Carmelita Sese

A Tumor Removed, A Life Regained

By: J. Tracy Hermann

Carmelita Sese

When Carmelita Sese came to the United States in 1985, she came looking for a better life than the one she left behind in the poor farming village tucked away in the Philippine countryside. At 15, she had already endured a lifetime of hardship and challenges. Her mother passed away from breast cancer when Carmelita was just four years old — an experience that she says will never quite leave her — and the day-to-day struggle to just survive in an impoverished community was at times overwhelming.

"It was a hard life, and I was eager to leave it behind and come to America to start a new life," Carmelita recalls feeling that June day not too many years ago. "I couldn't wait to get a job so that I could send money back to my family in the Philippines."

LEFT: CT Scanner at Eisenhower Imaging Center. ABOVE, FROM LEFT: Nurse Coordinators Barbara Bigelow, Leo and Gloria Rosen Infusion Center; Kim Von Haden, Eisenhower Schnitzer/Novack Breast Center; and Christal Curry, Radiation Oncology. Not pictured: Monica Alvarez, Arnold Palmer Prostate Center.

Sixteen years later, Carmelita has indeed crafted a new life with her husband, Jay, and their two children, Jay Christian (J.C.) and Jamie Lyn, a life that was really settling into something solid and sure. Along the way, she had earned a degree as a Medical Assistant and had worked her way up in a profession she felt passionate about. Jay also was happy and successful in his career as a dialysis technician, and the kids (now young teens) were doing well in school. Fate had its own notion of what was to be, however, and last year Carmelita's life took another — rather unexpected — turn.

"I began experiencing terrible headaches that would come and go," Carmelita recounts, tapping her foot anxiously on the floor. "I'd take some Tylenol® or Advil® and the headaches would go away for a little while, but the relief didn't last long.And then one morning, I woke up at 2 a.m. not feeling well and very thirsty. I made my way into the kitchen and just as I was about to open the refrigerator door, I passed out…I passed right out." "When he told me I had a brain tumor, I thought I was goint to die. All I could think about was my husband and my kids." - Carmelita Sese.

Carmelita regained consciousness some time later feeling very cold — "my body was so cold" — and frightened. As soon as she could, she made an appointment to see her family practitioner who diagnosed the 36-year-old, petite, and otherwise fit, Carmelita with hypertension, prescribed a regimen of 5 milligrams of Norvasc® and sent her home.

But as the weeks went on, the headaches continued and even worsened, and her vision began to blur. Then, one evening at work, she experienced an extremely debilitating bout of pain and dizziness.

"It felt like there was someone hammering in my head, so I lay down and asked my coworker to take my blood pressure, and it was high…it was really high," says Carmelita, reporting that her eyes were also red and watery and that she was vomiting uncontrollably. She had already picked her children up from school earlier in the day, and the three of them decided to stay at the office until Carmelita felt well enough to make the drive home to Yucca Valley.

At the urging of her employer, Svetlena Rubakovic, MD, Carmelita went for an MRI. She was initially diagnosed with hydrocephalus (fluid on the brain) and told not to worry. However, Dr. Rubakovic urged her to get a second MRI, and that's when fate — or good fortune — dealt a kinder hand; Carmelita was referred to Eisenhower neurosurgeon Farhad Limonadi, MD, for a consultation, and the very next day, she found herself in Dr. Limonadi's office awaiting her diagnosis.

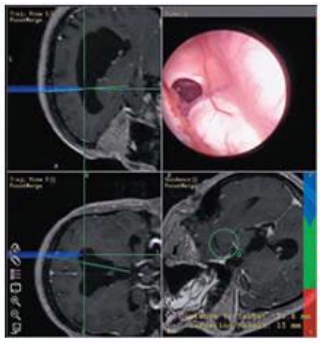

Intraoperatively, the location of the tip of the neuroendoscope (blue arrow) is monitored using computer-assisted stereotaxy and patient's MRI (left two pictures). The image is relayed to the computer system through the endoscope's camera system (right top picture). Distance to target is monitored on the right bottom picture. The two green circles, not superimposed on this picture, indicate a lock on the target is not yet obtained.

“Dr. Limonadi circled something on the film,” she recalls of those anxious moments in the doctor’s office. “When he told me I had a brain tumor, I thought I was going to die. All I could think about was my husband and my kids. He told me that I needed surgery right away, and that very same day I was admitted to Eisenhower.”

As a highly experienced neurosurgeon on the forefront of the discipline, Dr. Limonadi recognized immediately that Carmelita’s situation was extremely serious: “I noticed an abnormality in the area of the brain stem and sent her back for another MRI the same day, this time with a different sequence. The “flare” sequence showed, definitively, that there was a tumor in the brain stem, one of the busiest and most dense structures of the brain, packed with critical structures. Surgically, access to this area is risky and very difficult to achieve.”

“This area is essentially known among neurosurgeons as ‘No Man’s Land,’” Dr. Limonadi reports.

Indeed, even in modern times, the standard craniotomy (surgical removal of a section of bone from the skull) and approach to this deeply located tumor would have proven too risky, and many surgeons would have been tempted to just treat the tumor with radiation in hopes that it would slow its growth. However, thanks to technological advances in recent years and Dr. Limonadi’s extensive experience and background — and the help of one of his neurosurgical partners, Alfred Shen, MD — he was able to utilize two of the latest neurosurgical technological innovations: namely, stereotaxy (precise intra-operative, computer-assisted localization of brain structures) and neuroendoscopy (minimally invasive neurosurgery using small probes and cameras) to navigate the fissures of the brain. This was all done through a small incision “cosmetically fashioned” behind the hairline.

“Our objective was to, one, establish the exact diagnosis of the tumor (in order to guide appropriate therapy); two, remove the entire tumor (in order to improve the clinical outcome); and three, prevent Carmelita from becoming shunt dependent, which would require placing permanent tubing in her brain, neck and abdomen,” Dr. Limonadi recalls matter-of-factly. “We decided to marry these tasks with one procedure, a stereotactic neuroendoscopic third ventriculostomy (see box below) that allowed us to divert the fluid from the brain into another compartment and navigate the brain ventricular systems — without violating and injuring neighboring structures — and to successfully separate this malignant tumor from the brain stem.”

Three weeks later, a very alert and functional Carmelita Sese sits around a table at the Eisenhower Lucy Curci Cancer Center with her family, having just received instruction regarding her aftercare, which includes another Eisenhower exclusive — stereotactic radiation. She talks excitedly about her experience and her future… “I was walking immediately after my surgery; it was amazing! And look, it was just through this small incision,” she says, parting her hair to reveal a slight scar. “I can’t tell you how important it is to take these symptoms seriously and to get an MRI if you suspect anything is wrong. I feel great and I can see so much better now. It saved my life…Eisenhower and Dr. Limonadi saved my life…thank you, thank you, thank you for saving my life.”

Stereotactic Neuroendoscopy

Carmelita Sese’s “third ventricle” had a buildup of excess fluid. (The brain has four ventricles or chambers.) The typical surgical treatment for excess fluid (hydrocephalus) is to implant a flexible tube (shunt) in the brain to drain the excess fluid to another part of the body, commonly, the individual’s abdomen.

Eisenhower’s Farhad Limonadi, MD, was able to avoid the use of a shunt with the stereotactic neuroendoscopic third ventriculostomy. “Fifty percent of shunts fail within five years,” Limonadi reports. “Mrs. Sese would have been committed to tube replacements and have a significant rate of ongoing infection.”

The minimally invasive procedure uses an endoscope, a small probe with a light and camera, to carefully visualize and maneuver deep into the third ventricle, and then, to skillfully divert the fluid buildup to other fluid-filled areas of the brain. The “stereotactic system” guides the entire operation…not unlike an automobile’s Global Positioning System which helps navigate the car through streets and pathways, but for the brain.

Stereotactic Neuroendoscopy for minimally invasive brain surgery and the third ventriculostomy is routinely utilized by only a small fraction of neurosurgeons in the country. The neurosurgery team at Eisenhower is the only medical facility in Coachella Valley which utilizes this technology.

Healthy Living is a publication of Eisenhower Medical Center · © Copyright 2014 All Rights Reserved · www.emc.org